



PROLONGED FEBRILE SYNDROME CAUSED BY RETROPERITONEAL FIBROSIS

Al. Crișan, Emilia Nicoară, Ruxandra Laza

“Victor Babeș” University of Medicine and Pharmacy, 2nd Clinic of Infectious Diseases, Timișoara

Abstract. Because of its multiple causes, prolonged febrile syndrome often represents a real challenge. Clinical experience divides the causes of this syndrome into: infections (30-40%), neoplasia (10-30%), autoimmune diseases (9-15%), various other causes (15-20%), while 7-10% are of unknown origin. The case we report belongs to other causes group and stands out because it is a new entity among the causes identified in the past: hyperthyroidism, Addison's disease, Crohn disease, sarcoidosis, atrium myxoma, fever caused by drugs, pulmonary embolism etc. We present the case of a 52 year-old male patient with prolonged febrile syndrome and lumbar pain. The laboratory studies revealed nonspecific inflammatory syndrome and high BUN and serum creatinine levels. The abdominal ultrasound found a retroperitoneal mass and right hydronephrosis, while the computed tomography scan showed retroperitoneal fibrosis and identified the cause of the hydronephrosis: the right ureter was included in the fibrous process. A laparotomy was performed and revealed the retroperitoneal fibrosis localized in front of the lower part of the aorta and cava, under the kidneys, all the way to the emergence of the iliac vessels. The fibrous process involved both ureters. The histological exam confirmed the presence of a chronic, noninfectious fibrosis. Early diagnosis followed by surgical intervention prevented the occurrence of obstructive renal failure. The long-term prognosis depends on whether the fibrosis is a primary or a secondary process and whether it is associated with another immune pathology.

Keywords: prolonged febrile syndrome, lumbar pain, retroperitoneal fibrosis

Introduction

The decoding of the etiology of the prolonged febrile syndrome, as proposed by Petersdorf R. G. and Beeson P. B in 1961 follows an ascending and parallel curve along with the rising diversity and improvement of the diagnosing tools.

If in the 1930s Alt N. L and Barkev M. F reported an unidentified cause for the prolonged febrile syndrome in 78% of the cases, in 1980 this percent was only 7-10%.[1]

Extension of the traditional methods of di-

agnosis in the area of molecular medicine (genomics and proteomics) along with a less restrictive access to modern diagnosing techniques of great sensibility and specificity allows an early identification of the underlying cause, before the appearance of the classic signs and symptoms.

The causes of the prolonged febrile syndrome are frequently common diseases presenting in a non typical way, rather than rare diseases presenting in a typical way [2]. The nonspecific inflammatory pathology (diseases of the connective tissue, vasculitis, and granulomatous diseases) must not be ignored [3].

Localized fibrosis represents a category of diseases characterized by a fibrous process limited to an organ or tissue. In some cases it is localized deep within the organism (retroperitoneal fibrosis), while in other cases it is superficial (keloid,

Dupuytren), more prone to observation and study. Retroperitoneal fibrosis is a nonspecific, noninfectious inflammatory reaction of the fibrous adipose tissue localized in the Gerota space, which extends and compresses local structures: the ureter, cava, aorta and local nerves.

It is a deeply located, difficult to detect circumscribed fibrosis, which has an annual incidence of 1 case per 200.000-500.000 persons [4].

It is admitted that it is part of the spectrum of an entity called idiopathic systemic fibrosis. In two thirds of the cases the etiology remains unknown, the term "idiopathic" being well justified [5,6].

Occasional association with other autoimmune diseases, as well as the favorable response to cortisone and immunosuppressive therapy suggest an immune mediated pathophysiology [7,8].

The onset is nonspecific, initially with pain and then with fever, anorexia, dyspeptic syndrome, diarrhea, fatigability, weight loss and the progressive altered status.

While some causes of delay in establishing a diagnosis are linked to the patient and his tendency to minimize the symptoms and to postpone a potentially severe diagnosis, others are linked to medical negligence, omission and error. In our case report the delay went both ways [9,10].

We present the case of **N.R.**, a 52 years old male, from Timișoara, retired (complicated high blood pressure) hospitalized in our clinic for seven days, between 04.02.2009 -11.02.2009.

On admission, the patient presents with vesper fever and lumbar pain for 60 days. A urologic exam performed 30 days from the onset did not show any underlying cause in this area. The personal history reveals third stage essential high blood pressure (treated with Metoprolol, Enalapril and Indapamid), high serum cholesterol levels, hepatic steatosis. The familial history was non-contributory. The physical exam revealed a good overall status. The skin was pale, warm and we measured a temperature of 37,5°C. No other anomalies were found.

The clinical diagnosis suggested by the subjective and objective data was: prolonged febrile syndrome with lumbar pain.

Laboratory studies: Hb 11.4g/dl, L 5670/mm³, FL: N62% L27% M9% E2%, PLT: 250000/mm³, ESR 60/100mm/h/2h, RCP positive, Fibrinogen 7.6g%, serum glucose 104mg%, serum cholesterol 247mg%, serum triglycerides 75mg/dl, BUN 104mg%, serum creatinine 2.2mg%, TGP/TGO 20/11U/l, DB/TB 0.26/0.68mg%, AF 208U/l, GGTP 39U/l; serum

proteins: 6.73mg/dl, CA 19/9 = 25.91U/ml (VN < 37), ACE = 1.49ng/ml (VN < 10); Cultures (throat swab, nasal swab, urine culture, blood culture) were all negative.

Imaging studies

Plain lumbar column radiograph: Decreased lumbar lordosis and narrowed L3-L4 and L4-L5 intervertebral disks, with small lateral osteophytes. Calcified atheromatous plaques of the abdominal aorta. Suspicion of left ureteral stone or L3-L4 lateral osteophyte.

Abdominal ultrasound: The liver had a uniformly high echogenicity, with a caudate lobe of 27 mm. The gallbladder with biliary residue. The right kidney - dilated pyelocaliceal system. The left kidney - normal ultrasound appearance. Pancreas with uniformly high echogenicity and normal measurements. Abdominal aorta - high echogenicity walls without any aneurisms. Under the spleno-portal axis, in front of the aorta, a uniformly low echogenicity mass, with well delimited margins, which imprints part of the cava. A round shaped spleen with a diameter of 120 mm without any vascular dilatations.

The next stage diagnosis (based on the physical and ultrasound findings): retroperitoneal mass syndrome. Right hydronephrosis. Atheroma of the abdominal aorta. Liver steatosis.

The computed tomography scan revealed a retroperitoneal mass with irregular margins, which involved the aorta and the inferior cava from under the emergence of the renal arteries to the

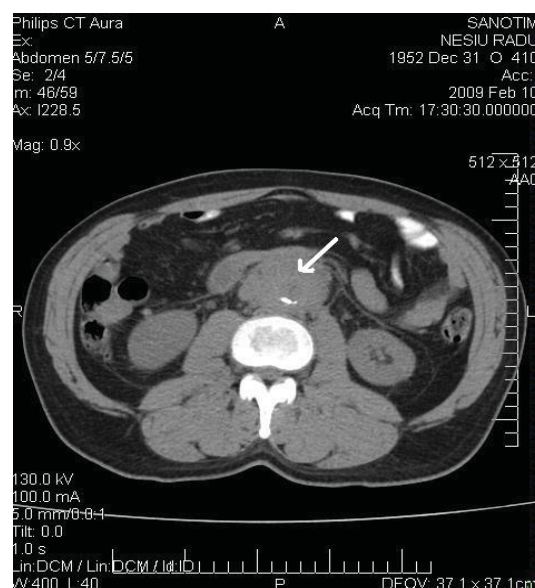


Figure 1. Retroperitoneal mass

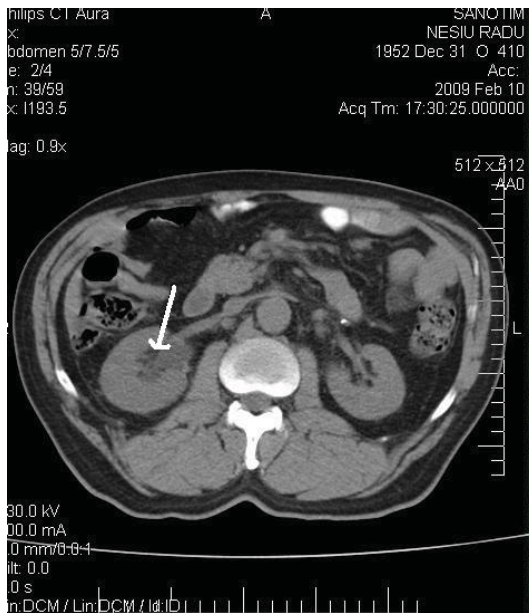


Figure 2. Right hydronephrosis

iliac bifurcation. It had a maximal measurement of 7,6/4,2/0,8 cm. Calcified parts of the abdominal aorta and common iliac arteries. The mass involved the right ureter in the lower lumbar region, which determined first stage, right hydronephrosis and delayed excretion of the right kidney.

The next stage diagnosis (based on the physical, ultrasound and CT scan findings): Retroperitoneal fibrosis. First stage, right uretero-hydronephrosis. Atheroma of the abdominal aorta. Liver steatosis.

The ultrasound findings in the absence of other data to support the diagnosis weren't satisfactory and could be disputed. The retroperitoneal fibrosis with secondary hydronephrosis diagnosis established by the CT scan led to an exploratory laparotomy.

The exploratory laparotomy showed a fibrous retroperitoneal mass, localized in front of the aorta and cava and below the kidneys before the emergence of the iliac vessels, which involved both ureters. The rest of the organs appeared to be intact. Multiple tissue samples were taken for the histopathological exam. The two ureters were decolated and placed in the parietocolic area.

The histopathological exam: white, elastic tissue fragments. Microscopy: nonspecific, chronic inflammatory fibrous process. It wasn't possible to exclude a benign fibrous histiocytoma. There weren't any malignant aspects.

The final diagnosis was: Retroperitoneal fibrosis complicated with first stage, right uretero-hydronephrosis and impaired renal function. Essential high blood pressure. Hypercholesterolemia.

Atheroma of the abdominal aorta. Liver steatosis (or fatty liver).

Particularities: The slowly progressing disease relatively delayed the necessary work-up. Still, the lumbar pain, the fever and the reno-urinary symptoms were enough to maintain at least a clinical follow-up. A better relationship between doctor and patient could have revealed the connection between the evolving abdominal mass and the symptoms sooner. The importance of the ultrasound faced with a group of less specific symptoms was yet again confirmed, although the CT scan did establish a more correct diagnosis. The nonspecific inflammatory syndrome should lead to extending the work-up concerning systemic scleroderma. Nor the surgical exploration, nor the histopathological exam did establish a certain etiology for the retroperitoneal fibrosis (idiopathic or consequence of a collagen disease or histiocytosis). Proper diagnosis followed by surgery prevented the onset of an obstructive renal failure. The BUN and serum creatinine levels went back to normal making the possibility of acute renal failure less likely (without taking into consideration the underlying cause of fibrosis).

Differentials:

During the clinical stage:

- Lumbar pain of extra renal etiology
 - Diseases involving the muscular and bone tissue of the lumbar column and pelvis
 - Idiopathic inflammatory myopathies (polymyositis, inclusion body myositis, myositis associated with collagen diseases, secondary/primary fibromyalgia) or specific inflammatory myopathies (septic myositis)
- Lumbar pain of renal origin (renal ptosis, pyelocaliceal stones, polycystic kidney disease, renal tuberculosis, renal neoplasia, acute and chronic pyelonephritis)
- Projected lumbar pain
 - From the bones: (multiple myeloma, osteoporosis, nonspecific/specific infections: staphylococcal spondylodiscitis/ Pott disease)
 - From the intervertebral disc: arthrosis, herniated disc
 - Articular: ankylosing spondylitis, chronic evolutive arthritis
- Extra renal abdominal pain: suppurative processes: perirenal abscess, psoas muscle abscess; tumors; retroperitoneal fibrosis; malignant lymphoma; colon flexure cancer

During the ultrasound stage:

- Secondary septic process from a nonspecific/specific spondylodiscitis evolving to a migratory abscess in the psoas region
- Localized, apparently primitive TB peritonitis, the fibro adhesive form
- Primitive/metastatic cancer, oncologic and hematologic disease
- Localized sarcoidosis

During the CT scan stage:

- Malignant diseases: lymphoma, sarcoma, metastases from lung, colon, liver, prostate cancer
- Periaortic inflammation (severe atherosclerosis)
- Chronic retroperitoneal inflammation
- Autoimmune diseases: scleroderma, membranous glomerulonephritis, systemic vasculitis, polyarteritis nodosa
- Tuberculosis

During the stage of surgical exploration and histopathological exam:

- A process of localized retroperitoneal fibrosis is confirmed
- The histopathological exam reveals histiocytosis, excluding for the time being an uncontrolled proliferation, Langerhans histiocytosis, hemophagocytic lymphohistiocytosis

Evolution, prognosis: depend on the primary or secondary type of the fibrous process, respectively localized idiopathic fibrosis or fibrosis as part of a collagen disease. In the case of evolutive localized fibrosis we must evaluate a possible association with other superficial (A) or deep (B) forms: A: palmar fibromatosis (Dupuytren contracture), developing keloid at minimal scarring; B: fibrosis of the endomyocard, pulmonary fibrosis (Hamman-Rich), mediastinal fibrosis, liver fibrosis: active chronic hepatitis, primitive biliary cirrhosis, primary sclerosing cholangitis, Riedel thyroiditis, Peyronie disease.

The short term evolution is favorable. Idiopathic retroperitoneal fibrosis has an excellent prognosis with minimal consequences on mortality and morbidity, even on the long run.

The long term prognosis is reserved due to the association with other pathologies, immune or not.

The treatment of choice is surgical: removing the retroperitoneal mass and decompressing the ureters in order to preserve renal function. Cortisone therapy could be effective, if administered before obstruction onset: Prednisolone 40-60mg/

day, lowering the dosage during 2-3 months to 10mg/day, completing the therapy after 12-14 months. Methylprednisolone pulse-therapy: 1g/day for 3 days, in association with Azathioprine or Penicillamine; steroids can be associated with surgery. Other things to consider:

- Inhibiting the activity of the proinflammatory cytokines with immunosuppressive (A) and immunomodulator (B) therapy: A.: Cyclophosphamide 1-3mg/kg. Higher doses of 200mg/kg offer a strong immunosuppression, immunologic ablation; Methotrexate 7.5mg/kg, 3/7: suppresses the primary as well as the secondary immune response.; B.: Monoclonal antibodies anti TNF α , anti IL6, IL10, IFN γ
- reducing fibrosis by decreasing collagen synthesis or by activating collagenases: D- penicillamine (interferes with collagen synthesis)
- Tamoxifen (nonsteroidal agent with antiestrogenic properties), decreases both TGF β secretion and synthesis: 10-40mg/day 6 months to 3 years. In comparison with steroids, it has little adverse effects and it is used especially in pulmonary embolism and ovarian cancer

In our case, the retroperitoneal mass was surgically removed, in order to decompress the ureters. The cortisone therapy was influenced (regarding both dose and duration of treatment) by the associated pathology.

Bibliography

1. Voiculescu M. Febris causa ignata, rev. *Viața Medicală* nr. 1, 1989;
2. Mackowiak PA, Durack DT. Fever of unknown origin, in: Mandell GL, Bennett JE, Dolin R, *Principles and Practices of Infectious Diseases, 6th Ed. Philadelphia: Elsevier; 2005: 718-727;*
3. Knockaert DC, Vanderschueren S, Blockmans D. Fever of unknown origin in adults, *J Intern Med* 2003; 253:263-75;
4. Tudor Aurica. Scleroza sistemică-Sclerodermia, Ed. Medicală, București, 2000;
5. Dejica D. *Tratat de imunoterapie*, Ed. Medicală, Cluj Napoca, 2006, pag. 543-551, 673-676;
6. Vaglio A, Salvarani C, Buzio C. Retroperitoneal fibrosis, *Lancet* 21-27 ian 2006; 367 (9506); 241-251;
7. Cronin CG, Lohan DG, Blake MA, Roche C, Mc Carthy P, Murphy JM. Retroperitoneal fibrosis: a review of clinical features and imaging findings; *Am J Roentgenol* Aug. 2008; 19 (2): 423-31;
8. Popescu ED, Ruxandra Ionescu. *Compendiu de hematologie*, Ed. Tehnică, București, 1997;
9. Vaglio A, Palmisano A, Corradi D, Salvarani C, Buzio C. Retroperitoneal fibrosis: evolving concepts; *Rheum Dis Clin North Am*. Nov 2007; 33 (4): 803-17;
10. Hsu THS, Strem SB, Nakada SY. Management of upper urinary tract obstruction; in: Wein AJ, ed. *Campbell-Walsh, Urology 9th Ed. Philadelphia, 2007: chap 38.*