



## TRICHINOSIS IN A PATIENT WITH FAMILIAL THROMBOPHILIA

Rodica Rusu

*Infectious diseases senior physician, Clinical Hospital of Infectious and Tropical Diseases „Dr. V. Babeş”, Bucharest*

---

**Abstract.** The author presents the case of an 11 year-old child who developed cerebral and peripheral vascular thromboses over a background genetic coagulation disease, revealed by a parasitic disease – trichinosis. The diagnosis was problematic and the clinical evolution was severe and prolonged due to the association of the two diseases and due to the patient’s precarious immune condition. The clinicians should be informed regarding the existence of a coagulation pathology, often ignored, whose prompt and correct diagnosis can save the patient’s life or ameliorate the disease’s evolution and prognostic.

**Keywords:** child, trichinosis, thrombophilia

---

### Background

The parasitosis is determined by the human intestine infestation with a nematode worm (*Trichinella spiralis*). Trichinosis exhibits a wide range of clinical symptoms, and is clinically characterized by: fever, myalgia (predominantly located in paravertebral and limb muscles), allergic phenomena (urticaria eruptions), periorbital and facial edema, non-specific neuropsychic symptoms (intense headache, apathy, asthenia, drowsiness, vertigo, confusion, delirium, agitation and/or convulsions, meningism, reflex diminution, at times even coma), myocarditis (of allergic mechanism, characterized by tachycardia, diminished cardiac sounds, altered rhythm – up to paroxystic tachycardia, gallop rhythm -, murmurs, arterial hypotension, non-specific ECG abnormalities), and it is

paraclinically characterized by: hyperleukocytosis with hypereosinophilia (the eosinophiles can reach percentages of 50–80%).

According to the quantity of ingested larvae, the resistance of the host-organism and its allergic reactivity, more or less severe clinical manifestations can be encountered. As such, there are numerous indistinct, asymptomatic (subclinical) outlines, which usually remain undiagnosed, and there are also mild, medium or severe outlines. The severe clinical outlines develop into toxic infectious syndrome in the full-blown stage of disease with the apparition of complications which can lead to death.

### Case presentation

The 11 year-old child S.W.A, from Bucharest, with two admittances to our clinic:

1. 5 – 9.01.
2. 17.01 – 11.02.

Upon first admittance, the child presents with: alimentary vomiting, extremely frequent watery diarrheic stools, diffuse abdominal pain (symptomatology with onset approximately 7 days prior to

hospital admittance) and a period of incoherence, temporal-spatial disorientation and aggressiveness, which preceded admittance by a few hours.

Patient history records: non-feverish onset, an ambulatory medical consult which had diagnosed acute enterocolitis and had recommended treatment with ciprofloxacin, symptomatics and diet, without amelioration of symptomatology.

*Physiologic personal antecedents:* single child, full-term delivery, normal weight, without delivery injury, with normal subsequent evolution.

*Pathologic personal antecedents:*

- remote: non-contributory;
- recent: a diarrheic episode in December, remitted post symptomatic treatment and diet.

Clinical examination upon first admittance: child with mediocre clinical status, non-feverish, conscious, with no motor deficits, no signs of meningeal irritation, discrete non-pruriginous micro-maculo-erythematous exanthema (which persisted for approximately 24 hours), cardio-respiratory equilibrated, VA = 78/min, BP = 90/60mmHg, supple abdomen, diffusely sensitive to palpation, very frequent watery stools.

Paraclinically noteworthy were: full blood count, ESR, glycemia, creatinine - all within normal limits, the seric ionogram registered: hypopotassemia, (2.9mmol/l) and hyponatremia (132mmol/l).

On the evening of the first day of admittance the patient's state abruptly worsened, with temporal-spatial disorientation, psycho-motor agitation, aggressiveness, "encephalitic cry". PL was performed in the absence of meningeal irritation signs and fever but in the presence of the neuropsychic manifestations and a clear hypertensive CSF was extracted, with Pandy reaction +/- with 30 nucleated elements/mm<sup>3</sup>, CSF biochemical exam within normal limits. The clinical manifestations are considered an outline of acute encephalitis and the following treatment is started: dexamethasone 20mg/day, cerebral depletives (Mannitol 20% 400ml/day), neurotropes, endovenous perfusion for hydro-electrolytic reequilibration, protection antibiotic (Ceftriaxone).

On the 2<sup>nd</sup> day of admittance: onset of right facial central type paresis and right hemiparesis.

On the 3<sup>rd</sup> day: cyanosis of the right lower limb and consequent paleness and coldness with "sock"-like distribution on the skin of the same limb, with barely discernible peripheral pulse of the region.

Given the syndrome of motor deficit of the right

hemibody, a cranial computed-tomography was performed, and it showed: left fronto-temporo-parietal hypodensity 4/3/5,6 cm, diffusely delimited, non-iodophilic, through which the blood vessels had normal trajectory; hypodensities of smaller dimensions with bilateral parietal location; stained contrast grip on the prefrontal gyri and on the cranial vault.

The cranial MRI showed: extensive acute thrombosis of the cerebral venous sinuses (superior sagittal, rectus and lateral sinuses), with edematous parcellar left fronto-parieto-temporal venous infarction, without mass effect, without hemorrhagic transformation; diffuse moderate cerebral edema; without suppurative focal point in the O.R.L. territory (see images)

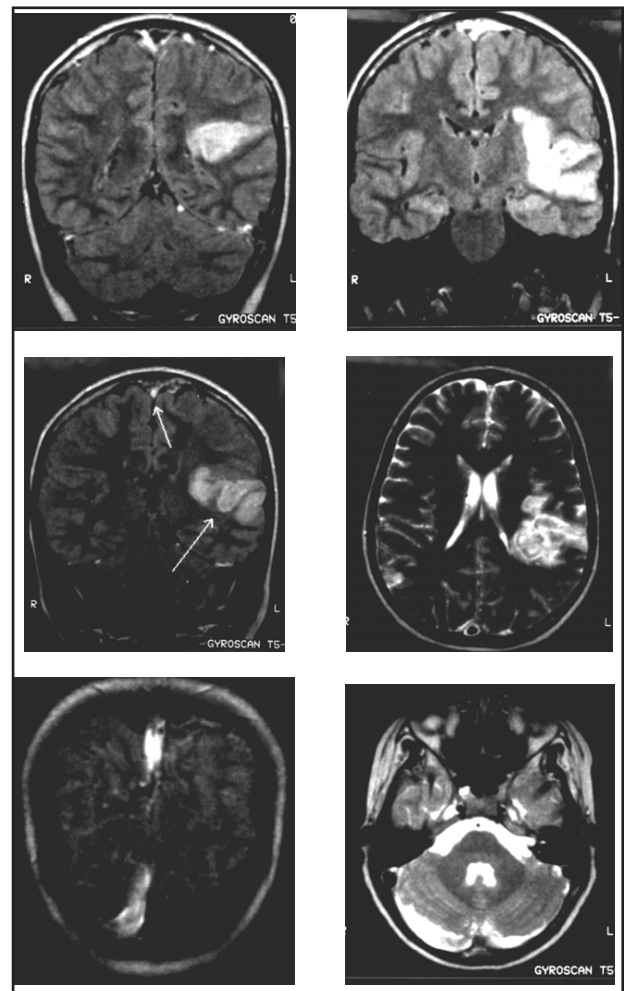


Figure 1. Cranial MRI images

Consequently to these investigations, the neurosurgeon recommends transfer to the neurosurgery clinic of the „Bagdasar” hospital, for treatment of the cerebral sinuses' thrombosis, which was initiated in our clinic in the day before transfer (heparin in

continuous perfusion).

Subsequently, after the examination within the clinic of other family members presenting with myalgia, headache, periorbital edema, and based on the epidemiologic data (collective consume of pork meat without prior trichinoscopic examination), the relatives have been diagnosed with - clinical, hematological and/or serological - trichinosis.

The subsequent epidemiologic investigation with the mother revealed the fact that in December the patient consumed pork meat without prior trichinoscopic examination, but denied the presence in that timeline of symptoms in other family consumers; after approximately two weeks from the first admittance, the mother of the child notices the presence of periorbital edema and myalgia in some of the consumers of the incriminated meat and the laboratory investigations performed in ambulatory regimes for the relatives have revealed the presence of blood eosinophilia, and/or positive ELISA serology for *Trichinella spiralis*.

This was when the child was retransferred to our clinic, the ELISA serology for *Trichinella spiralis* being positive in the S.W.A. child as well.

Upon clinical examination for readmittance, the following was observed: child with altered clinical status, non-feverish, conscious, pale, accusing myalgia in limbs, with *ecchymoses* on the venous puncture marks, peri-nail cyanosis in the fingers of the right lower limb, with paleness and coldness of the skin of the right limb—up to the ankle, barely discernible peripheral pulse of the region., plantar and bilateral palpebral edema, right facial central type paresis, right hemiparesis, contracture of the masseters and of the paravertebral muscles; respiratory equilibrated, with VA = 112/min, BP = 120/80 mmHg, with diminished cardiac sounds, systolic pluri-orifice murmur, supple abdomen, with liver and spleen within normal parameters, semi-solidified stools.

Paraclinically: leukocytosis (19.500/mmc), with neutrophilia (89% PMN), without eosinophilia (1.65% = 311/mmc). ESR = 23mm/h, 51mm/2h; increased CPK value (758u/l); ionic altering (hypopotassemia = 3.1mmol/l, hypochloremia = 82mmol/l, hypocalcemia = 7.7mmol/l), hypoproteinemia (PT = 4.9mg%). The coproculture was repeatedly negative, the coprocytologic exam revealed Charcot Leyden crystals.

Abdominal echography showed no pathological altering, and the cardiologic consult revealed a preserved contractile function, with non-specific

terminal phase ECG abnormalities.

Antiparasitic treatment was started: Albendazol (600mg/day) for 14 days, corticotherapy (HHC – 400mg/day), electrolytic and proteic reequilibration (molar electrolytic solutions, human albumin 20%). Because of the persisting clinical manifestations which attested the presence of venous thromboses and arterial occlusions (cerebral and peripheral), the cardiologist doctor recommended associated anticoagulant treatment.

After a vascular surgery consult and a vascular Doppler exam, the diagnosis of right subpopliteal thrombosis was confirmed and the first line treatment was anticoagulant with Heparin in doses of 300u/h, in continuous perfusion.

Permanent monitoring of the following was performed: urinary and seric ionogram, proteinemia, coagulation indexes.

Since the patient's grandmother, (admitted to our clinic within the same timeline with the trichinosis diagnosis) suddenly developed stenosis of the left subclavian artery, the suspicion of a familial coagulation pathology arose, which led to the intensification of the specialty hematological investigations in members of the whole family. The laboratory results confirmed the diagnosis of thrombophilia (father-inherited), which explained the substrate of the cerebral sinuses' thromboses, such as the thromboses of the peripheral vascular system (popliteal artery) in our patient.

The patient's evolution under the mentioned treatment was favorable, with remission of the facial paresis and of the right hemibody paresis, receding of edema, myalgia and muscle contractures, correction of the ionic dissemblance and of the hypoproteinemia, with significant amelioration of the right lower limb ischemia.

## Discussions

Thrombophilia – is a hypercoagulability state which can be hereditary or acquired.

The laboratory investigations which back up a hereditary thrombophilia are:

1. presence of the V Leiden factor
2. activated protein C resistance (APCR)
3. protein C deficit
4. protein S deficit
5. mutation on the prothrombin gene 20210
6. hyperhomocysteinemia MTHFR

The activated protein C exerts its anticoagulant effect through the proteolytic neutralization of the

factors Va and VIIa. Most of the cases of activated protein C resistance have a single point mutation on the factor V gene, where arginine 506 is replaced with a glutamic residue. This determines the cleavage site of the activated protein C from this position to become resistant to proteolysis, determining the factor V Leiden to become resistant to inactivation through protein C. More than 95% of the patients with APCR have factor V Leiden. Factor V Leiden heightens the risk of venous thrombosis – approximately 5 – 10 times in heterozygotes, respectively 50 – 100 times in homozygotes.

Factor V Leiden is the most frequent hereditary coagulation anomaly. It is present in approximately 5% of the white population and in only 1,2% of the African population.

Factor V Leiden is associated with the following complications:

- venous thromboses such as:
  - deep-vein thromboses in the upper and lower limbs,
  - superficial thrombophlebitis
- pulmonary embolism which may produce:
  - cerebral venous sinuses thrombosis,
  - thromboses of the mesenteric veins,
  - Budd-Chiari syndrome
- cerebral vascular accidents or transient ischemic attack (regardless of age), coronary ischemia
- repeated spontaneous abortions
- preeclampsia and/or eclampsia.

Diagnosis of thrombophilia through factor V Leiden is suspected in patients with chronic history of venous thromboses, or in families with high incidence of venous thromboses. The diagnosis is confirmed either through a coagulation screening test or through genetic tests for the F5 gene which codes for the protein of factor V. Factor V Leiden is inactivated 10 times slower than the normal factor V and persists longer in the blood flow, resulting in an increased production of thrombin and a state of hypercoagulability reflected in the high levels of F1+2 fragments and of other markers activated by coagulation. Subsequently, genotype analysis is necessary for determining the state of homozygote or heterozygote, essential for the long term conduit.

Testing for the factor V Leiden should be performed under the following clinical circumstances:

- first episode of venous thrombosis before 50 years of age;
- first episode of venous thrombosis without

favoring factors at any age;

- recurrent venous thrombosis;
- venous thromboses with atypical location (cerebral, mesenteric, portal, hepatic);
- venous thromboses during pregnancy, perinatally or associated to the oral contraceptive treatment, or to substitution hormonal therapy;
- first episode of venous thrombosis in patients with family history of venous thromboses;

Testing for the factor V Leiden could be considered under the following clinical circumstances:

- asymptomatic adults, from families with diagnosed cases of thrombophilia with factor V Leiden, particularly those with family history of thromboses at young ages;
- asymptomatic pregnant women, or those who desire pregnancy or initiation of oral contraceptive therapy;
- women with spontaneous abortions of unknown cause in the II<sup>nd</sup> or III<sup>rd</sup> trimester of pregnancy;
- selected cases of women with preeclampsia, premature placental separation, or delay of intrauterine growth;
- women with a first episode of venous thrombosis associated to tamoxifen treatment, or other selective modulators for estrogen receptors;
- smoking women, under 50 years of age, with myocardial infarction;
- people over 50 years old with a first episode of venous thrombosis of unknown cause, in the absence of a malignancy or of intravascular implants.

## Conclusions

Trichinosis, associated in the presented case with an extremely severe diarrhea, with significant electrolytic altering, was the triggering factor for exteriorizing a hereditary coagulation ailment

The clinicians should be informed regarding the existence of this coagulation pathology, which can have its onset in childhood age as well, whose prompt recognition can save the patient's life or the physical and/or psychological integrity of the patient.

## References

1. Proulx J-F et al. Novel prevention program for trichinosis in Inuit communities. *J. of Clin. Infect. Dis* **34**, **11**, p. 1508 – 1514.

2. **Schantz PM.** Trichinosis in US, 1947 – 1981, *Food Technol.* **1983**, **37**: 83 – 6.
3. **Baily TM, Schantz PM.** Trends in the incidence and transmission patterns of trichinosis in humans in the U.S.: comparison of the periods 1975 – 1981 and 1982 – 1986. *Rev. Infect. Dis.*, **1990**; **12**: 5 – 11.
4. **Fourestie V et al.** Randomized trial of albendazole versus tiabendazole plus flubendazole during on outbreak of human trichinosis. *Parasitol. Res.* **1988**; **75**: 36 – 41-
5. **Gherman J.** *Trichineloză și chistul hidatic. Bucuresti, Edit. ALL, 1994, 1 – 77-*
6. **Rebedea I și colab.** Evolutia clinica a trichinelozei. *Rev. Rom. De Parazitologie*, **1993**; **2**: 64 – 65.
7. **Zanc V.** *Trichinosis Parazitologie clinica – Nematode; sindroame de larva migrans. Partea a II-a, Nematode tisulare. Edit. SINCRO, 2001, 135 – 164.*
8. **Jody L K et al.** Factor V Leiden Thrombophilia. *GENE Reviews*, **2002**.
9. **Kupfermanc JF et al.** *Increased frequency of Genetic Thrombophilia in Women with complications of Pregnancy. New England J. of Med. Vol. 340, 9 – 13.*
10. **Heit JA et al.** Risk factors for deep-vein thrombosis and pulmonary embolism: a population-based case-control study. *Arch Intern Med* **2000**, **160**: 809 – 815.
11. **Koster T et al.** Role of Clotting Factor VIII in Effect of Willebrand Factor on Occurrence of DVT. *Lancet* **1995**, **345**: 152 – 155.
12. **O'Donnell TE et al.** High prevalence of elevated factor VIII levels in patients referred for thrombophilia screening: Role of increased synthesis and relationship to acute phase reaction. *Thrombosis & haemostasis*, **1997**, **77(5)**: 825 – 8.
13. **Van Der Meer FJM et al.** The Leiden Thrombophilia Study (LETS). *Thrombosis & Haemostasis*. **1997**. **78(1)**: 631 – 635.
14. **Heijmans BT et al.** The risk of mortality and the factor V Leiden mutations in a population-based cohort. *Thromb. & Haemost.* **80**: 607 – 609.