



NAIL-PATELLA SYNDROME – CASE REPORT

Stoica Cristina¹, Chiriac-Babei Gh.¹, Vasilescu Mariana¹, Matei Roxana², Lungu A.¹, Joiteanu Monica¹

¹ Fundeni Clinical Institute – Pediatric-Nephrology Department, Bucharest, Romania

² National Institute of Infectious Disease "Prof.Dr.Matei Balș", Bucharest, Romania

Abstract. The authors present the case of a sixteen year-old boy with significant family history (father with chronic kidney disease who received a living related donor kidney transplant), admitted in our department for hematuria, skeletal abnormalities and “antecubital pterygia”. The renal function and systemic involvements were evaluated and imagistic tests were performed. A surveillance and therapeutic plan were performed.

Keywords: antecubital pterygia, nephropathy, onychodysplasia, LMX1B gene, hypoplastic patella

Introduction:

Nail-patella syndrome (NPS) is a rare autosomal-dominant disorder characterised by: *onychodysplasia*, hypoplasia or absence of the patellae, iliac horns, elbow abnormalities, renal disease (inconstant). Affected individuals may also exhibit eye disorders and sensorineural deafness [1]. It is also known as: Turner-Kieser syndrome, Fong disease, hereditary osteo-onychodysplasia, iliac horn syndrome [2].

The incidence has been estimated at one in 50,000 individuals. The disease has been reported in patients worldwide, affecting males and females equally [1].

Genetics.

In NPS patients a variety of LMX1B gene defects are identified (missense, splicing, insertion/deletion and nonsense mutations) [3,4]. The gene has been localised to the distal end of chromosome nine (9q34) [4,5]. It was recently shown that LMX1B regulates the coordinated expression of type IV collagen alpha-3 and alpha-4 in the glomerular base-

ment membrane (GBM) and that its dysregulation in the GBM contributes to the nephropathy [6]. It also has been suggested that there may be two allelic mutations of the gene: one responsible for the NPS without nephropathy and one responsible for the NPS with nephropathy. It has been calculated that, for a parent with NPS with nephropathy, the risk of having a child with nephropathy is 24%, and the risk for progression to end stage renal disease is 7% [7].

Clinical features

Onychodysplasia occurs in 80-90% of patients. Over 90% of NPS patients exhibit abnormalities of the knee – hypoplastic or absent patella. Common elbow changes are dysplasia of the radial head, hypoplasia of the lateral epicondyle, prominence of the medial epicondyle, antecubital pterygia which may result in dislocation of the radial head, limitation of extension, pronation and supination of the forearm. Iliac horns observed in about 80% of the patients are pathognomonic for NPS [8,9]. Other bone involvement may consist of cervical rib, hypoplasia of the lateral femoral condyle and the humeral condyles (capitellum), small head of the fibula, scoliosis [10]. Renal involvement occurs in less than half of the NPS patients. Symptoms include microscopic hematuria and mild proteinuria, which typically appear in adolescence or young adulthood. Occasionally patients develop nephrotic syndrome (NS), hypertension, renal failure [11].

Cristina Stoica,

Fundeni Clinical Institute, Pediatric Nephrology
Department

email: drcristinastoica@yahoo.com

Other systemic involvements include ophthalmic problems (cataract, glaucoma) [12], sensorineural hearing loss and, occasionally, mental retardation.

Pathology

The nephropathy of NPS has no specific features by light microscopy or routine immunofluorescence. Electron microscopy reveals the pathognomonic and constant lesions of the GBN [13,14,15].

Case report

Male patient, G.C.V., 16 years old, was admitted in our pediatric nephrology department for diagnosis and treatment because of hematuria observed at a routine urinalysis. His personal medical history revealed that as an infant he underwent a surgical procedure for right shoulder dislocation. At that time they noticed an elbow malformation (the forearms are in flexion, at 90° with impossible further extension and limitation of the extension).

His present physical examination showed normal height for his age with lower body mass index, elbows in flexion at 90°, with impossible further extension, the skin and the underlying forearm flexor muscle form a stretched cord which limits the extension (pterygium antecubital) (fig 1a, 1b).

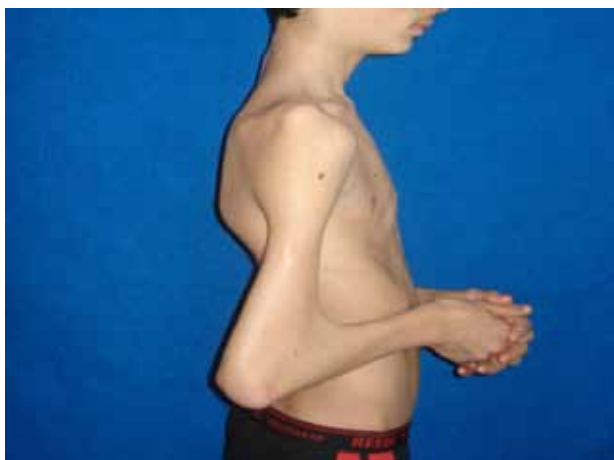

Figure 1a. Elbow malformation, the forearms at 90° flexion, with limitation of the extension

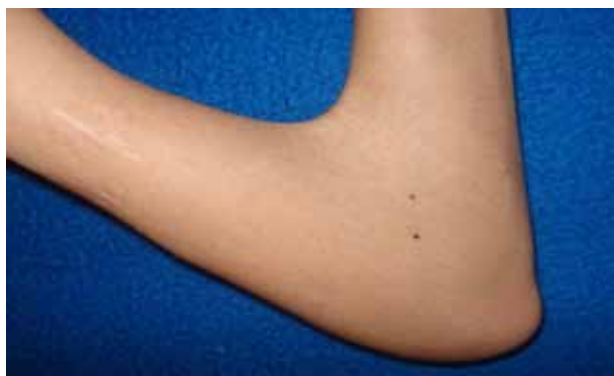

Figure 1b. Pterygium antecubital

The patient also presented onychodysplasia, especially of the thumbnails (fig 2a, 2b), bilateral absence of patella (fig. 3), deformed chest, scoliosis, hypoplastic upper arm muscles (fig. 4 a, 4 b), left shoulder subluxation (fig. 5).

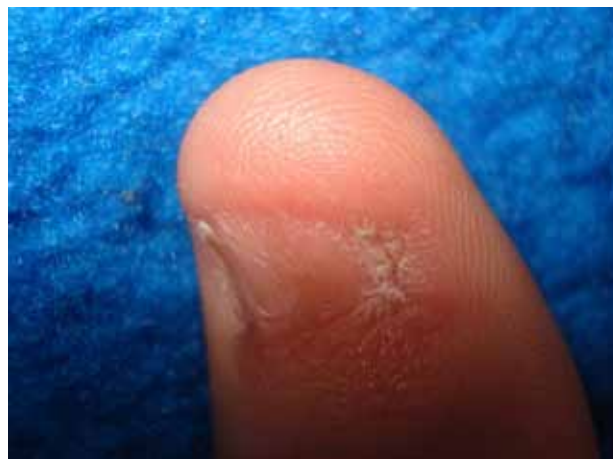

Figure 2a. Onychodysplasia of the thumbnail

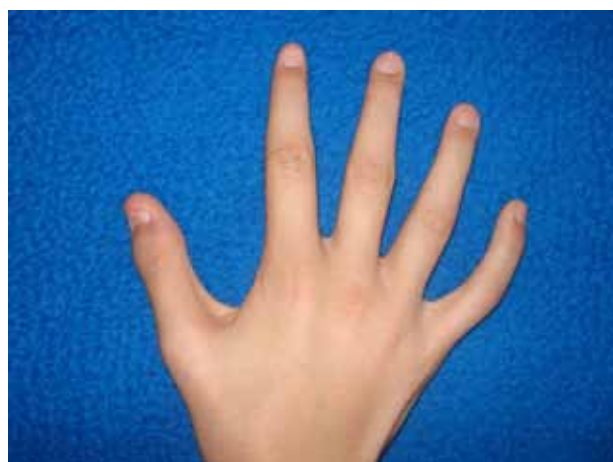

Figure 2b. Onychodysplasia

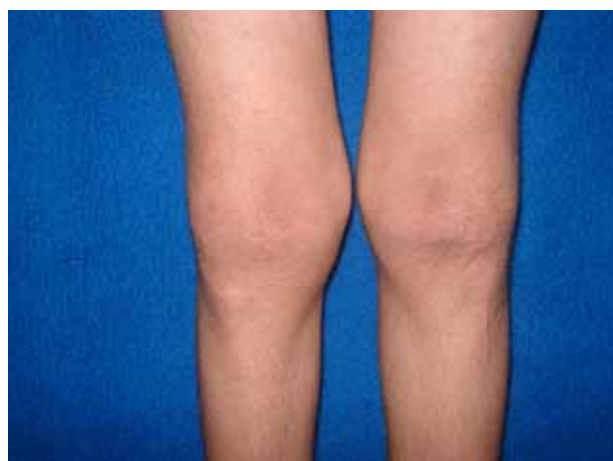

Figure 3. Bilateral absence of patella

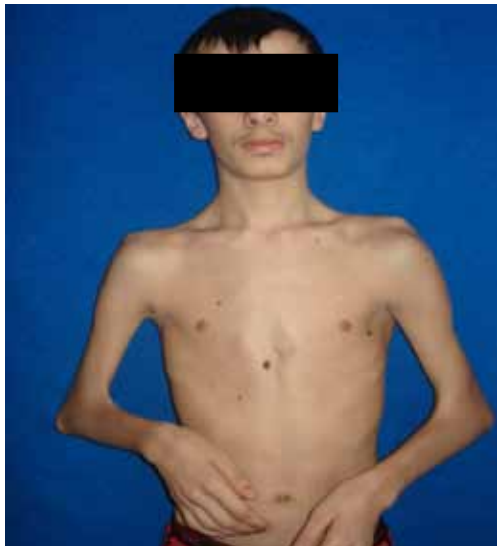

Figure 4a. Deformed chest, hypoplastic upper arm muscles

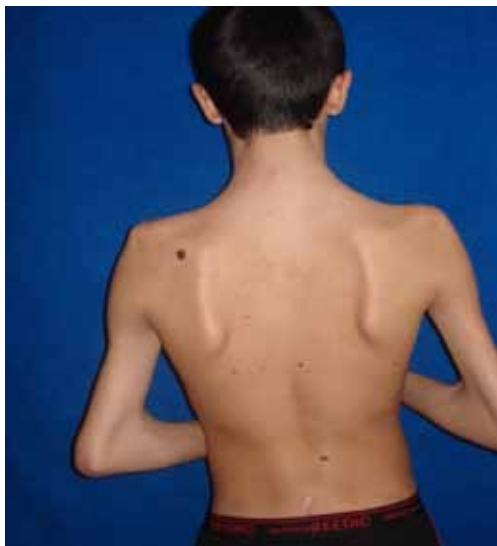

Figure 4b. Scoliosis, hypoplastic upper arm muscles

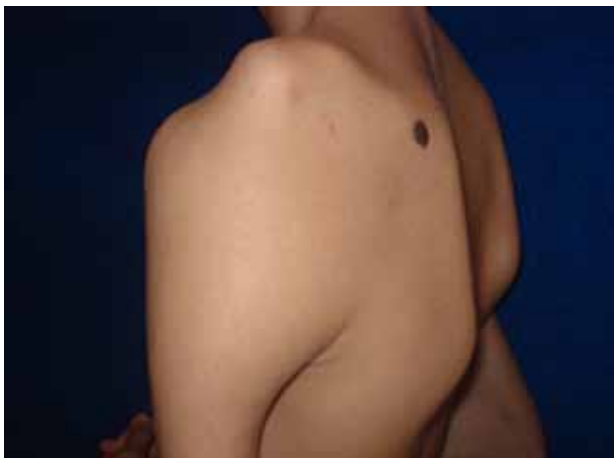

Figure 5. Left shoulder subluxation

Skeletal X-rays performed confirmed the clinical findings (fig 6, 7, 8).

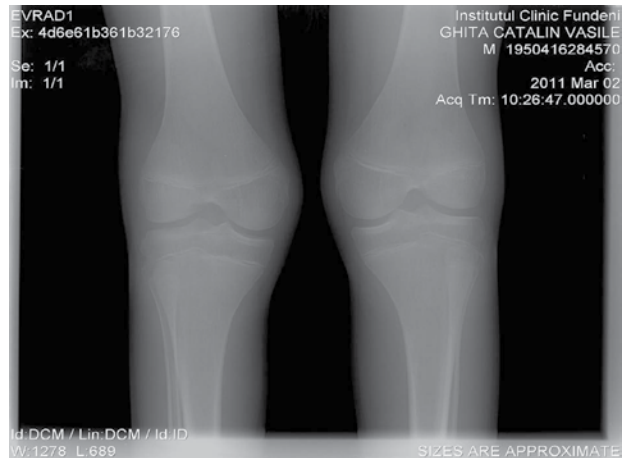


Figure 6. Knee X-Ray - bilateral absence of patella

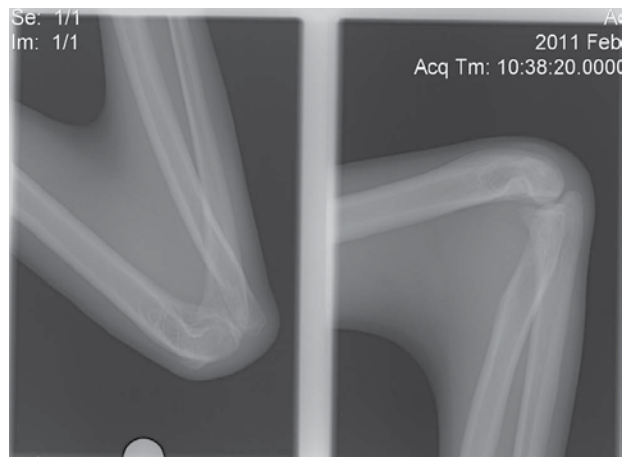

Figure 7. Upper Arm X-Ray – elbow in flexion, at 90°, with impossible further extension, the skin and the underlying flexor muscles of the forearm form a stretched chord.

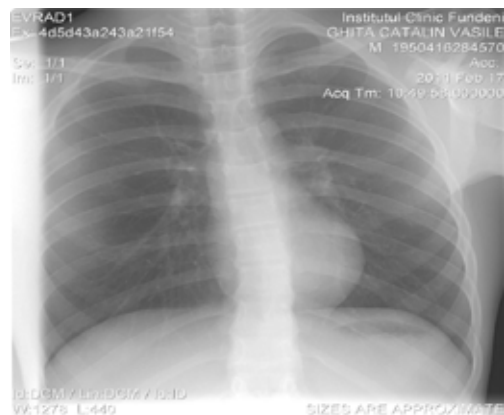


Figure 8. Chest X-Ray - scoliosis

Syndrome	Similarities	Differences
Small patella syndrome (ischioapatellar dysplasia, coxo-podo-patellar syndrome, Scott-Taor syndrome)	Small or absent patellae Recurrent patella dislocations Pelvic anomalies	Defective ossification at the ischiopubic junction Ischial hypoplasia Infra-acetabular „axe-cut“ notch No nail changes No elbow changes No renal involvement No ocular involvement [16]
Patella aplasia-hypoplasia (PTLAH)	Isolated aplasia OR Hypoplasia of the patella	No nail changes No elbow changes No renal involvement No ocular involvement
Familial recurrent dislocation of the patella	Familial tendency toward patella dislocation	
Meier-Gorlin syndrome	Absent patellae Dislocation of the radial head	Microtia Markedly short stature Delayed bone age Characteristic facial appearance Autosomal recessive inheritance
Genitopatellar syndrome	Absent patellae Renal anomalies Flexion deformities of the knees and hips Club foot	Hypoplasia of the ischia and iliac bones Genital anomalies Facial dysmorphism Microcephaly Intellectual disability Structural (multicystic kidneys or hydronephrosis) rather than functional abnormalities Renal manifestations [17]
DOOR syndrome	Absent or poorly formed nails	Long thumbs and big toes, often with triphalangy Other fingers and toes short as the result of an absent or hypoplastic distal phalanx Bilateral ptosis Short broad nose with a broad nasal tip and large nostrils Structural renal tract abnormalities Cataract Optic atrophy Dandy-Walker malformation Seizures Autosomal recessive inheritance [18]
Trisomy 8 mosaicism	Absent or hypoplastic patellae Limited elbow supination Abnormal nails	Significant learning difficulties Variable facial dysmorphism Camptodactyly and progressive joint restriction, usually of the fingers and toes
Coffin-Siris syndrome	Absence or hypoplasia of the nails and patellae Elbow dislocation	Nail hypoplasia, usually affecting the little finger nails Facial dysmorphism [18]
RAPADILINO syndrome	Radial defects Absent or hypoplastic patellae Dislocated joints	Cleft palate Facial dysmorphism Short stature Radial defects, including absent or hypoplastic thumbs and radii Autosomal recessive inheritance [18]
Senior syndrome	Small nails	Characteristic facial appearance Short stature Mild intellectual impairment

Table I. Differential diagnosis of nail-patella syndrome

We note that his father has the same clinical findings (bilateral absence of patella, bilateral antecubital pterygium, onychodysplasia and subluxation of the humeral joints). He also developed end stage renal failure (ESRF) and received a live, unrelated donor kidney transplant.

Routine laboratory tests were unremarkable with the exception of low serum protein levels (5.3 g/dl), hypercholesterolemia (210 mg/dl), hematuria and abnormal telescoped urinary sediments. Proteinuria was 2.49 g/l/24h.

Considering the family history, the clinical findings that were imagistically confirmed and the laboratory tests, our diagnosis was nail-patella syndrome with antecubital pterygium and renal involvement.

After this initial diagnosis, in order to establish the extent of disease the following evaluations were performed: screening for cataract and ocular hypertension, neurologic, gastrointestinal, dental or vasomotor abnormalities.

In order to evaluate the extent of the nephropathy, a renal biopsy was attempted but the lack of cooperation of the patient prevented this investigation to be done.

Discussions

We took into consideration the following differential diagnoses with other syndromes where antecubital pterygium, onychodysplasia, hypoplasia of the patella are present (table 1).

Surveillance and therapeutic plan.

There is no specific treatment available.

Our patient needs plastic surgery for antecubital pterygium together with physiotherapy in order to gain an adequate flexion angle of the elbow and improve his quality of life by helping himself independently.

Patellae absence is not affecting his activity, except for performance.

The patient will also receive ACE inhibitors to possibly slow the progression of proteinuria and to control the blood pressure (if hypertension will develop).

His surveillance plan includes annual monitoring for hypertension and renal disease (urinalysis, albumin-creatinine ratio on first morning urine, urea, creatinine blood levels). A screening for glaucoma/ataract should be also performed every year.

Considering that NPS is inherited in an autosomal dominant manner genetic counseling and family planning is recommended.

The offsprings of a proband are at 50% risk of inheriting NPS, but disease severity cannot be predicted.

Prenatal diagnosis for pregnancies at risk is now possible by analysis of DNA extruded from fetal cells

obtained by amniocentesis usually performed at 15-18 weeks gestation. The disease-causing allele of an affected family member must be identified before prenatal testing can be performed. Although this testing can determine whether or not the fetus has inherited the *LMX1B* disease-causing mutation, it cannot predict the appearance or severity of clinical manifestations [19].

Ultrasound examination may also be useful because talipes equinovarus or large iliac horns may be detected on fetal ultrasound examination in the third trimester of pregnancy.

We also recommend screening for his family members because if a parent is affected, his family members are at risk.

Conclusions

NPS is a rare disease. We note that this patient was diagnosed late despite all significant clinical findings and having been seen by doctors from an early age. Many patients with NPS seek medical attention for seemingly unrelated pathologies. In many instances, the radiologist may be the first to make the clinical diagnosis based on the findings from the routine imaging examinations.

The clinical manifestations are extremely variable in both frequency and severity with inter and intra familial variability.

The prognosis is based on the degree of renal involvement.

Our patient requires special attention with close monitoring given the presence of renal involvement and his family history. If the progression will be towards ESRD he will require a live, unrelated donor kidney transplant, with carefully performed selection since NPS is an autosomal dominant transmitted disease.

References:

1. Ellis D, Avner, William E. Harmon, Patrick Niaudet, Norishige Yodhikawa. *Pediatric Nephrology – Sixth Edition*, Ed. Springer-Verlag, 2009:630-641,
2. Jones KL *Smith's Recognizable Patterns of Human Malformation*, 5th ed, Saunders, 1997:24-27,
3. Dreyer SD, Zhou G, Baldini A, Winterpacht A, Zabel B, Cole W, Johnson RL, Lee B. Mutations in *LMX1B* cause abnormal skeletal patterning and renal dysplasia in nail patella syndrome. *Nat Genet* 1998;19:47–50.
4. Vollrath D, Jaramillo-Babb VL, Clough MV, McIntosh I, Scott KM, Lichter PR, Richards JE. Loss-of-function mutations in the LIM-homeodomain gene, *LMX1B*, in nail-patella syndrome. *Hum Mol Genet* 1998;7:1091–1098.
5. Chen H, Lung Y, Ovchinnikov D, et al, Limb and kidney defects in *Lmx1b* mutant mice suggest an involvement of *LMX1B* in human nail patella syndrome. *Nat Genet*, 1998; 19:51

6. **Morello R, Zhou G, Dreyer SD, Harvey SJ, Ninomiya Y, Thorner PS, Miner JH, Cole W, Winterpacht A, Zabel B, Oberg KC, Lee B.** Regulation of glomerular basement membrane collagen expression by LMX1B contributes to renal disease in nail patella syndrome. *Nat Genet* 2001;27:205–208.
7. **Looij BJ, Te Slaa, RL, Hogewind, BL, van de Kamp JJ.** Genetic counseling in hereditary osteo-onychodysplasia with nephropathy. *J Med Genet* 1988; 25:682
8. **Meyrier A, Rizzo R, Gubler M-C.** The nail-patella syndrome: a review. *J Nephrol* 1990;2:133–140.
9. **Bongers EM, Gubler MC, Knoers NV.** Nail-patella syndrome. Overview on clinical and molecular findings. *Pediatr Nephrol* 2002;17:703–712.
10. **Ioannis A. Ignatiadis, Achilleas S. Kepenekidis, Maria Z. Goudesidou, Christos K. Giannakopoulos, Georgios H. Papadopoulos.** Turner-Kieser Syndrome with „Antecubital Pterygia“. *Romanian Journal of Hand and Reconstructive Microsurgery* 2001; 1-2:41-46
11. **Sweeney E, Fryer AE, Mountford RC, Green AJ, McIntosh I.** Nail patella syndrome: a study of 123 patients from 43 British families and the detection of 16 novel mutations of LMX1B. *Am J Hum Genet* 2001;69(Suppl):A571
12. **Lichter PR, Richiards JE, Downs CA, Stringham HM et al** Cosegregation of open-angle glaucoma and the nail-patella syndrome, *Am J Ophthal* 124: 506–515, 1997.
13. **Del Pozo, E. Lapp. H.** Ultrastructure of the kidney in the nephropathy of nail-patella syndrome. *Am J Clin Pathol* 1970;54:845
14. **Ben-Bassat M, Cohen L, Rosenfeld J.** The glomerular basement membrane in the nail-patella syndrome. *Arch Pathol* 1971;92:350–355.
15. **Hoyer JR, Michael AF, Vernier RL.** Renal disease in nail-patella syndrome: clinical and morphologic studies. *Kidney Int* 1972;2:231–238.
16. **Bongers EM, Duijf PH, van Beersum SE, Schoots J, Van Kampen A, Burckhardt A, Hamel BC, Losan F, Hoefsloot LH, Yntema HG, Knoers NV, van Bokhoven H.** Mutations in the human TBX4 gene cause small patella syndrome. *Am J Hum Genet.* 2004;74:1239–48.
17. **Cormier-Daire V, Chauvet ML, Lyonnet S, Briard ML, Munnich A, Le Merrer M.** Genitopatellar syndrome: a new condition comprising absent patellae, scrotal hypoplasia, renal anomalies, facial dysmorphism, and mental retardation. *J Med Genet.* 2000;37:520–4.
18. **Winter R, Baraitser M.** *London Dysmorphology Database.* 2.2 ed. Oxford, UK: Oxford University Press. 2000.
19. **Hawkins CF, E. SO.** Renal dysplasia in a family with multiple hereditary abnormalities including iliac horns. *Lancet* 1950;1:803–808.